

# Postlaminectomy lumbar pseudomeningocele with nerve root entrapment: a case report with review of literature

Ramin Kamali · Zahra Naderi Beni ·  
Afsaneh Naderi Beni · Mohsen Forouzandeh

Received: 22 November 2011 / Accepted: 20 December 2011 / Published online: 4 January 2012  
© Springer-Verlag 2011

**Abstract** Pseudomeningocele is a rare but well-recognized complication of lumbar surgery. Most of the patients tolerate the presence of the cyst well, however, some present with back pain and spinal claudication, presumably due to neural compression. We report a case who presented with radicular symptoms and signs after disk surgery. The cause of his pain was nerve root herniation into large pseudomeningocele. The diagnosis was made by magnetic resonance imaging. The patient underwent surgery for the pseudomeningocele with reduction in the nerve root into the dural canal and primary closure of the dural defect. Postoperative results were gratifying.

**Keywords** Lumbar spine surgery · Pseudomeningocele · Nerve root entrapment

## Introduction

Postsurgical pseudomeningoceles are relatively rare complications of spinal surgery that have received little attention in both the neurosurgical and radiologic literature [1].

Pseudomeningoceles are defined as extradural collections of cerebrospinal fluid (CSF) with no dural covering, which usually result from an inadvertent meningeal tear or inadequate closure during spinal surgery [1–4].

The exact incidence of postoperative pseudomeningocele is unknown because many of these patients are asymptomatic [5]. The literature sporadically reports cases of pseudomeningocele and the associated complications. Pseudomeningocele is an extremely rare cause of spinal cord compression. Few cases have been reported in the literature, and in all of them, the spinal cord compression was located in the cervical region [6–9].

Herniation of the cervical cord into a pseudomeningocele has been reported [10].

A trapped nerve root of the pseudomeningocele can also occur and cause radicular pain [11].

Nerve root herniation into pseudomeningoceles has rarely been reported and is not well discussed [11]. We report a patient with large symptomatic postlaminectomy lumbar pseudomeningocele with nerve root.

## Case report

A 34-year-old man presented to our outpatient clinic in April 2009 complaining of severe low back pain that radiated down to his left foot that started a year prior. His complaints were aggravated by coughing and straining, and relieved by bed rest. He was also experiencing numbness and a tingling sensation in his left great toe.

---

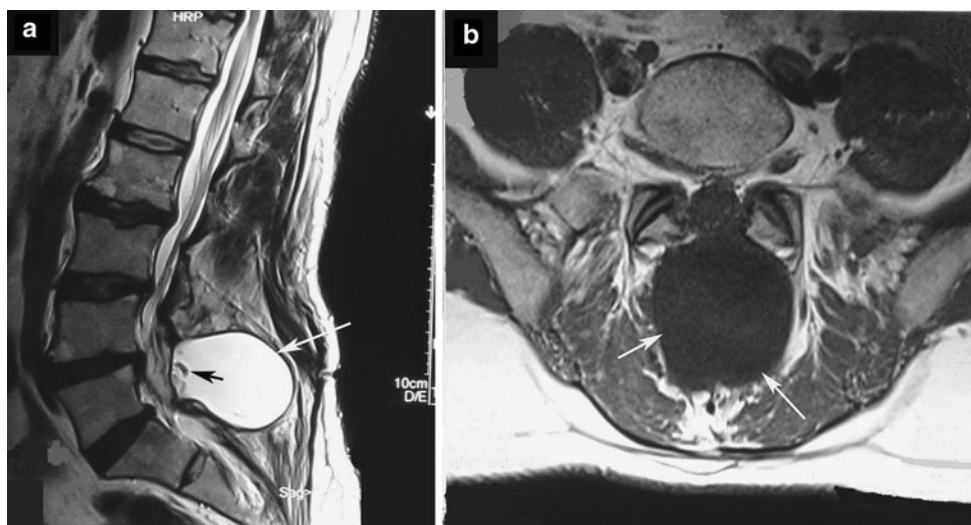
R. Kamali  
Department of Neurosurgery, Shahrekord University of Medical Sciences and Health Services, Shahrekord, Iran

Z. Naderi Beni  
Shahrekord University of Medical Sciences and Health Services, Shahrekord, Iran

A. Naderi Beni  
Department of Ophthalmology, Shahrekord University of Medical Sciences and Health Services, Shahrekord, Iran

A. Naderi Beni (✉)  
Kashani Hospital, Shariati Sq., Shahrekord, Iran  
e-mail: a\_naderibeni@yahoo.com

M. Forouzandeh  
Department of Radiology, Shahrekord University of Medical Sciences and Health Services, Shahrekord, Iran



**Fig. 1** T2-weighted MRI of the lumbar spine in the sagittal plane **a** and T1-weighted in the transversal plane **b** showing a large pseudomeningocele (white arrows) at L4–L5 level, containing herniated cauda equina fibers (black arrow)

On physical examination, only active flexion of the lumbar spine elicited pain. All other active ranges of motion were negative. The straight leg raise (SLR) test was positive only on the left side, with a 45° angle raise. The patellar and Achilles' tendon reflexes were intact. There was no weakness of plantar flexion strength; however, he exhibited weakness in dorsiflexion of the left foot (4/5). Sensory deficit on the left L5 dermatoma was revealed. Lumbar MRI showed L4–L5 disk herniation. He was given conservative therapy but this failed to relieve his symptoms after 2 months and surgery was offered.

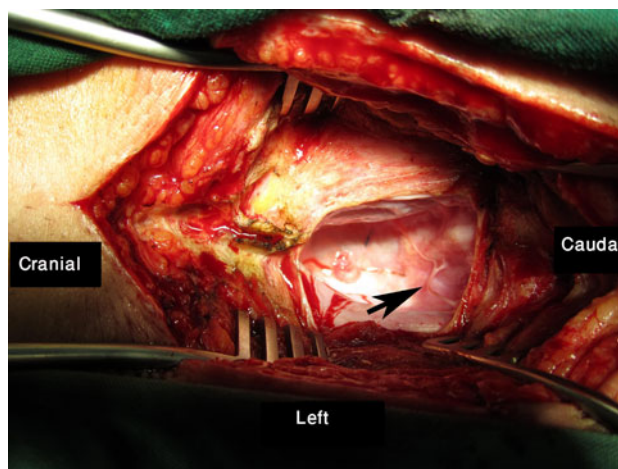
The patient underwent L4 laminectomy, L4–L5 discectomy, and L5 left foraminotomy.

Dural tear or CSF leakage in the dura was not observed.

The patient had a good postoperative recovery, and at the time of discharge (postoperative day 2), the patient had improvement of left leg pain. At 2 weeks, 1, and 3 months review, the patient's neurological examination was normal.

One year after the first operation, the patient presented with left leg pain, left L5 hypoesthesia, and paresthesia. The neurological examination showed a painful straight leg raise on the left side. The MRI showed an extradural cyst (length, 45 mm; width, 55 mm; depth, 65 mm) in the lumbar paraspinal area. The cyst cavity seemed to be connected with the subarachnoid spaces and to compress the cauda equina. Furthermore, one or more cauda equina fibers appeared to herniate through a small dura defect (Fig. 1).

A postoperative pseudomeningocele was considered. Because of the patient's progressive symptoms, operative treatment was indicated. At operation, the skin was opened through the old operation scar and a subcutaneous cyst from L4 to S1 was identified. The cyst cavity was opened, and clear fluid was evacuated. A pseudomeningocele-containing multiple left L5 root, herniating through a small

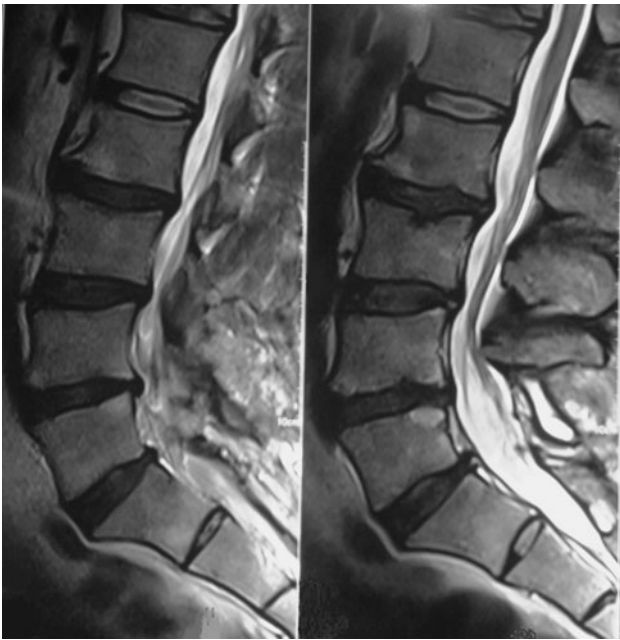

**Fig. 2** Intraoperative photography demonstrates the pseudomeningocele's cavity and the defect in the dural closure and nerve root entrapment in cavity (arrow)

defect in the thecal sac was identified (Fig. 2). After enlargement of the dura defect, left L5 root was released and replaced intradurally. The dural defect was repaired primarily with interrupted 4–0 sutures, and the pseudomeningocele was resected. After 5 days of bed rest, the patient was discharged. Magnetic resonance imaging performed 2 weeks after the repair of the pseudomeningocele demonstrated resolution of pseudomeningocele (Fig. 3). The patient had no complaints on 12 months follow-up.

## Discussion

Pseudomeningocele, on the other hand, is almost always of iatrogenic origin and is not associated with congenital anomalies [12–14]. They do rarely occur after trauma [15].



**Fig. 3** Postoperative sagittal spinal MRI shows the resolution of the pseudomeningocele with small remnant cyst, but there is no pressure effect

A pseudomeningocele can be a postoperative complication of laminectomy and is the result of an incidental dural tear [16–21].

Postoperative pseudomeningocele was first reported by Hyndman and Gerber in 1946 in a survey of extradural Cysts [22]. The terms “meningocele spurious,” “pseudocyst,” or “false cyst” have also been used to describe pseudomeningoceles [23–25].

Like a meningocele, a pseudomeningocele is a CSF-containing cyst, but the wall of the cyst consists of scar tissue rather than a meningeal membrane. This report concerns an iatrogenic pseudomeningocele in the lumbar region.

Lumbar disk surgery is the most common operation performed by neurosurgeons. Fortunately, postoperative pseudomeningocele formation is very rare. The true incidence of postlaminectomy pseudomeningocele is not known as many are thought to be asymptomatic. Some series report an incidence of <1% [26, 27], but others as high as 2% [3].

Pseudomeningoceles are thought to be formed in one of two ways. In one, a tear occurs in both the dura and arachnoid, and chronic CSF leakage leads to the development of a pseudocyst from abnormal connective tissue reaction in the paraspinal region. In another, intact arachnoid herniates through a dural defect created at the time of operation and causes formation of an arachnoid-lined pseudomeningocele. The first mechanism is largely responsible for the formation of pseudomeningoceles, the

second mechanism, with an arachnoid-lined pseudomeningocele, is rare [28].

During surgery, if the dura is accidentally torn, but the arachnoid is intact, the arachnoid may herniate through the defect to the epidural space resulting in extradural cyst. More frequently, however, both are torn, allowing CSF to leak into the paraspinal soft tissues. Initially, the CSF is easily absorbed, but later, the progressive connective fibrous reaction hinders the reabsorption and CSF accumulates in the paravertebral tissues and finally a pseudomeningocele occurs. Subsequently, either the CSF is resorbed or it becomes encapsulated by fibrous tissue, thus resulting in a pseudomeningocele. Sometimes, nerve roots may herniate into the pseudomeningocele cavity [23, 29–31].

In our patient, there were neural structures in the cavity. Pseudomeningoceles may slowly enlarge, and they usually make their presence known as an unsightly lump under the skin, usually under the incision from a spine operation [12–14]. They are often not especially painful but may leak spinal fluid as they enlarge [32]. They may compromise the function of surrounding structures by compression, but usually this is not a major issue because the vast majority of pseudomeningoceles form along the incision line and there are few vital structures in the area [13].

It may cause radicular symptoms and result in irreversible neural damage. In this patient, the lesion involved the L4 level and the radicular symptoms were seen at the L5 level. Headaches may be seen with large pseudomeningoceles. A palpable fluid collection may be found if it extends through the lumbosacral fascia [2].

The interval between laminectomy and discovery of the pseudomeningocele varies from a few months to many years. This interval was approximately 12 months in our case. The size of the cyst is determined by the CSF pressure and the resistance of the paravertebral tissues [28].

The most common complaint is lumbar pain in symptomatic cases. The symptoms can be difficult to distinguish from persistent or recurrent symptoms after discectomy. Hematoma formation, nerve root inflammation, and extrusion or sequestration of residual disk fragments, transdural nerve root herniation, and entrapment in the intervertebral space [33] are the causes of recurrent sciatica in early postoperative period and disk extrusion or sequestration from the same or alternative level, nerve root fibrosis are the main causes of delayed recurrence. On rare occasions, a pseudomeningocele has been implicated as a cause of persistent pain from pressure on a nerve root by the cystic mass [34]. A lumbar pseudomeningocele rarely may present with recurrent radicular pain, because of compression of a nerve root, or entrapment of the nerve root in the neck of the cyst [11, 28]. The symptoms can be difficult to distinguish from persistent or recurrent symptoms after discectomy.

Occasionally, patients complain of motor weakness or sphincter disturbance due to involvement of the nerve roots, but most are small and asymptomatic [1]. According to Miller and Elder, there is no correlation between the size of the cyst and the degree of symptoms [23].

Our patient's symptoms were probably due to compression, because nerve root entrapment was found upon operation. Excision of the cyst and repair of the dural defect results in symptom improvement and a good prognosis.

Asymptomatic pseudomeningoceles may be observed. Although as before, it may be difficult to distinguish symptoms from a pseudomeningocele from recurrent/persistent symptoms necessitating surgery in the first place. The pseudomeningocele did not resolve after 12 months of observation, owing to the presence of a dural defect. Resolution was achieved by closure of the dural defect. Surgical treatment is recommended in cases of symptomatic nerve root herniation to avoid further neurological deterioration. Nonetheless, conservative methods should be considered as initial treatment [35].

Treatments include cyst aspiration and fibrin patches. Definitive treatment consists of reduction in herniated roots and primary closure of the dural defect. The defect may be closed with a dural graft, the pseudomeningocele sac itself, or fibrin glue. The entire sac need not be removed.

We believe that a postoperative pseudomeningocele should be suspected in patients submitted to lumbar discectomy when delayed postoperative neurological deficit occurs even many months or years after the surgical procedure. Surgical treatment is required in symptomatic cases to prevent progressive neurological damage. Any dural opening made during lumbar surgery should be tightly closed at the time of the original operation.

The case in the current report illustrates an unusual but significant cause of recurrent sciatica and nerve root herniation demonstrated in sagittal section of magnetic resonance imaging and detected at operation time.

**Acknowledgments** Special thanks to Dr Ali Naderi Beni for his assistance in the manuscript preparation.

**Conflict of interest** Authors do not have any financial interest in the subject matter of this article.

## References

- D'Andrea F, Maiuri F, Corriero G, Gambardella A, La Tessa G, Gangemi M (1985) Postoperative lumbar arachnoidal diverticula. *Surg Neurol* 23:287–290
- Barron JT (1990) Lumbar pseudomeningocele. *Orthopedics* 113:608–610
- Teplick JG, Peyster RG, Teplick SK, Goodman LR, Haskin ME (1983) CT identification of postlaminectomy pseudomeningocele. *AJR Am J Roentgenol* 140(6):1203–1206
- Kim YW, Unger JD, Grinsell PJ (1974) Postoperative pseudo-diverticular (spurious meningoceles) of the cervical subarachnoid space. *Acta Radiol Diagn* 15:16–20
- Lee KS, Hardy IM (1992) Postlaminectomy lumbar pseudomeningocele: report of four cases. *Neurosurgery* 30:111–114
- Hosono N, Yonenobu K, Ono K (1995) Postoperative cervical pseudomeningocele with herniation of the spinal cord. *Spine* 20:2147–2150
- Hanakita J, Kinuta Y, Suzuki T (1985) Spinal cord compression due to postoperative cervical pseudomeningocele. *Neurosurgery* 17:317–319
- Helle TL, Conley FK (1981) Postoperative cervical pseudomeningocele as a cause of delayed myelopathy. *Neurosurgery* 9:314–316
- Burres KP, Conley FK (1978) Progressive neurological dysfunction secondary to postoperative cervical pseudomeningocele in a C-4 quadriplegic: case report. *J Neurosurg* 48:289–291
- Dunn V, Smoker WR, Menezes AH (1987) Transdural herniation of the cervical spinal cord as a complication of a broken fracture fixation wire. *AJNR Am J Neuroradiol* 8:724–726
- O'Connor D, Maskery N, Griffiths WE (1998) Pseudomeningocele nerve root entrapment after lumbar discectomy. *Spine* 23:1501–1502
- Jenkins AL, Deutch H, Patel NP, Post KD (2004) Complication avoidance in neurosurgery. In: Winn R, Scott RM (eds) *Youman's neurological surgery*, 5th edn. Elsevier, Philadelphia
- Roberts M (1988) Complications of lumbar disc surgery. *Spinal Surg* 2:13–19
- Nairus JG, Richman RJ, Douglas RA (1996) Retroperitoneal pseudo-meningocele complicated by meningitis following a lumbar burst fracture. A case report. *Spine* 21:1090–1093
- Aldrete JA, Ghaly R (1995) Postlaminectomy pseudomeningocele. An unsuspected cause of low back pain. *Reg Anesth* 20:75–79
- Eismont FJ, Wiesel SW, Rothman RH (1981) Treatment of dural tears associated with spinal surgery. *J Bone Joint Surg (Am)* 63:1132–1136
- Koo J, Adamson R, Franklin CW, Hrdy DB (1987) A new cause of chronic meningitis: infected lumbar pseudomeningocele. *Am J Med* 86:103–104
- Maiuri F, Corriero G, Giamundo A, Donati P, Gambardella A et al (1988) Postoperative cervical pseudomeningocele. *Neurochirurgia* 31:29–31
- Murayama S et al (1989) Magnetic resonance imaging of post-surgical pseudomeningocele. *Comput Med Imaging Graph* 13:335–339
- Nash CL, Kaufman B, Frankel VH (1971) Postsurgical meningeal pseudocysts of the lumbar spine. *Clin Orthop* 74:167–177
- Schmacher HW, Wassman H, Podlinski C (1988) Pseudomeningocele of the lumbar spine. *Surg Neurol* 29:77–78
- Hyndman OR, Gerber WF (1946) Spinal extradural cysts, congenital and acquired: report of cases. *J Neurosurg* 3:474–486
- Miller PR, Elder FW Jr (1968) Meningeal pseudocysts (meningocele spurious) following laminectomy. Report of ten cases. *J Bone Joint Surg Am* 50:268–276
- Cook DA, Heiner JP, Breed AL (1986) Pseudomeningocele following spinal fracture. A case report and review of the literature. *Clin Orthop Relat Res* 247:74–79
- Pagni CA, Cassinari V, Bernasconi V (1961) Meningocele spurious following hemilaminectomy in a case of lumbar discal hernia. *J Neurosurg* 18:709–710
- Schumacher HW, Wassman H, Podlinski C (1988) Pseudomeningocele of the lumbar spine. *Surg Neurol* 29(1):77–78
- Swanson HS, Fincher EF (1947) Extradural arachnoidal cysts of traumatic origin. *J Neurosurg* 4:530–538
- Tsuji H, Handa N, Handa O et al (1990) Postlaminectomy ossified extradural pseudocyst. *J Neurosurg* 73:785–787



29. Hadani M, Findler G, Knoler N, Tadmor R, Sahar A, Shacked I (1986) Entrapped lumbar nerve root in pseudomeningocele after laminectomy: report of three cases. *Neurosurgery* 19:405–497
30. Rinaldi I, Peach WF Jr (1969) Postoperative lumbar meningocele. *J Neurosurg* 30:504–507
31. Wilkinson HA (1971) Nerve root entrapment in “traumatic” extradural arachnoid cyst. *J Bone Joint Surg* 52:163–165
32. Pavlou G, Bucur SD, van Hille PT (2006) Entrapped spinal nerve roots in a pseudomeningocele as a complication of previous spinal surgery. *Acta Neurochir (Wien)* 148:215–220
33. Toppich HG, Feldmann H, Sandvoss G, Meyer F (1994) Intervertebral space nerve root entrapment after lumbar disc surgery. *Spine* 19:249–250
34. Crenshaw AH (1987) *Campbell’s operative orthopaedics*, 7th edn. CV Mosby Company, St. Louis, pp 3300–3301
35. Johnson JP, Lane JM (1998) Traumatic lumbar pseudomeningocele occurring with spina bifida occulta. *J Spinal Disord* 11:80–83